

Contents lists available at [SciVerse ScienceDirect](#)

## The Journal of Arthroplasty

journal homepage: [www.arthroplastyjournal.org](http://www.arthroplastyjournal.org)

## Rotational Alignment of the Femoral Component Using Trochlear Navigation During Total Knee Arthroplasty: A Dual-Center Study of 145 Cases

Philippe Piriou MD, PhD<sup>a</sup>, Etienne Peronne MD<sup>b</sup>, Hervé Ouanezar MD<sup>c</sup>

<sup>a</sup> Raymond Poincaré Hospital, Raymond Poincaré, Garches, France

<sup>b</sup> La Châtaigneraie Clinic, Rue de la châtaigneraie, Beaumont, France

<sup>c</sup> Fellow, Lyon Hospitals, Lyon, France

## ARTICLE INFO

## Article history:

Received 4 March 2013

Accepted 17 April 2013

Available online xxx

## Keywords:

total knee arthroplasty  
computer-assisted surgery  
femur  
rotation  
reproducibility of results  
intraoperative care

## ABSTRACT

Rotational alignment of the femoral component during TKA is critical. Here we propose a technique using navigation of the femoral trochlea to determine the rotation of the femoral component. The rotation is considered “ideal” when the component position leads to the arthroplasty trochlea being perfectly superimposed over the native trochlea. Thus the arthroplasty trochlea will be aligned on the trochlear groove axis, which itself is perpendicular to the transepicondylar axis. This was a prospective, non-randomized, dual-center study involving 145 knees. In all knees, the rotation of the femoral component was determined intraoperatively by trochlear navigation. The alpha angle obtained with this method was compared to the one calculated on a preoperative or postoperative CT scan. There was excellent agreement between the results obtained with the CT scan method and the ones obtained with trochlear navigation.

© 2013 Elsevier Inc. All rights reserved.

During total knee arthroplasty, adjusting the femoral component rotation is an important element of the surgical technique. Substantial debate exists over how to accomplish this [1]. The component rotation influences the anatomical result through its effect on the flexion gap and influences the clinical result mainly through its effect on patellofemoral alignment [2,3]. Several methods exist to perform this rotational alignment, but none are sufficiently precise [4]. Intraoperative determination of the transepicondylar axis, either visually or by surgical navigation, is not reliable or reproducible [5–7]. Empirically setting 3° of external rotation, whether using the dependent or independent cut method, is not appropriate because of the individual variability in operated knees. The angle formed by posterior condylar axis and transepicondylar axis (called the posterior condylar angle or alpha angle) is subject to significant individual variation [8–10].

We developed an innovative technique using surgical navigation of the femoral trochlea to determine the femoral component rotation. Femoral component rotation is considered ideal when the component position leads to the arthroplasty trochlea being perfectly superimposed over the native trochlea on 30°, 60° and 90° sunrise views of the patellofemoral joint during the femoral planning. Thus the bottom of the arthroplasty trochlea will be aligned on the trochlear groove

axis (located during the trochlear bone morphing), which itself is perpendicular to the surgical transepicondylar axis [11]. This method also allows the tension on the medial and lateral patellar retinaculum to be properly balanced. This should help to center and balance the arthroplasty patellofemoral joint, thus preserving the kinematics of the extensor mechanism.

The goals of the current study were first, to show that trochlear navigation is a reliable and reproducible method to set the femoral component rotation relative to the reference transepicondylar axis, and second, to show that the flexion gap configuration is not negatively affected when this method is used to set the rotation.

### Materials and Methods

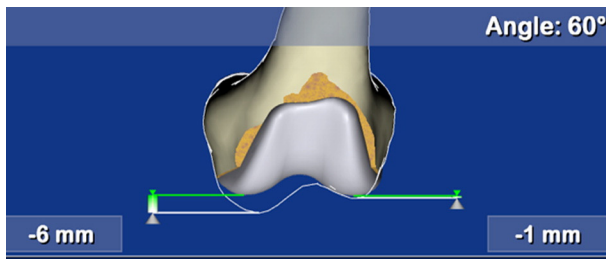
This was a prospective, non-randomized, dual-center study involving 145 continuous patients who were recruited at two French hospitals by two senior surgeons. All patients were enrolled in 2010 and were reviewed at 3 months and 1 year following the procedure. There was no patient screening because every patient was enrolled consecutively at both centers. During preoperative and postoperative visits, every patient was given a clinical examination and radiological evaluations, which consisted of long-leg standing films, weight-bearing x-rays and 30 year and 60 year sunrise views of the patellofemoral joint. In terms of morphology, patients with significant deformity (greater than 20° in varus or valgus) were not included in the analysis. In this series, 17% of knees had patellofemoral osteoarthritis (isolated or associated with tibiofemoral osteoarthritis). In 11% of cases, this osteoarthritis was

The Conflict of Interest statement associated with this article can be found at <http://dx.doi.org/10.1016/j.arth.2013.04.032>.

Reprint requests: Philippe Piriou, MD, PhD, Raymond Poincaré Hospital, 104 Boulevard Raymond Poincaré, 92380 Garches, France.

0883-5403/0000-0000\$36.00/0 – see front matter © 2013 Elsevier Inc. All rights reserved.  
<http://dx.doi.org/10.1016/j.arth.2013.04.032>

Please cite this article as: Piriou P, et al, Rotational Alignment of the Femoral Component Using Trochlear Navigation During Total Knee Arthroplasty: A Dual-Center Study of 14..., J Arthroplasty (2013), <http://dx.doi.org/10.1016/j.arth.2013.04.032>



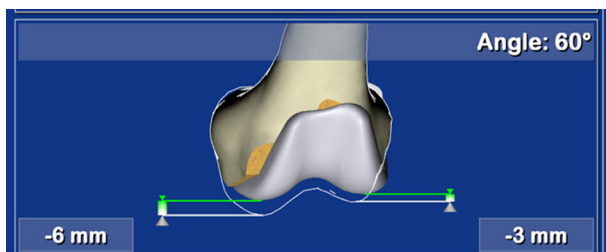
**Fig. 1.** Surgical planning view of the knee in 60° flexion BEFORE the rotation is adjusted. The position of the arthroplasty trochlea is compared to the native trochlea. By default, the femoral implant is parallel to the posterior condylar axis; external rotation of 0°.

associated with lateral patellar subluxation. There were no cases of permanent lateral patellar dislocation.

Patients were treated with a mobile bearing, ultra-congruent Score primary arthroplasty (Amplitude, France) and the surgery performed using a navigation system (Amplivision, Amplitude, France). A medial parapatellar surgical approach with lateral dislocation of the lateral extensor mechanism was performed in all cases with less than 10° valgus or varus. In the other cases, a lateral approach without tuberosity displacement was performed. The patellar retinaculum was cut only when subluxation of the extensor mechanism was present initially. A technique called “cementless patella embedding” was used at both centers. The polyethylene inlay implant was forcefully placed into a reamed area centered over the patellar ridge. The retaining shape of the central peg helps to fix the implant until peripatellar fibrosis can occur.

The navigation software uses a bone-morphing technique to help plan the position of the joint arthroplasty components. The surgeon palpates a series of points on the distal epiphysis of the tibia and the femur, with emphasis on the femoral trochlea. A three-dimensional model transforms itself to correspond to the shape of the patient's distal femur and tibia at the palpated points. The maximum error in the model is 1 mm at the palpated points. Once the morphometric data have been recorded, the surgical strategy consisted of balancing the knee in extension by releasing the ligaments enough to obtain a 180° HKA angle (mechanical axis of the lower extremity). In all cases, the femoral component rotation was determined using the “trochlear navigation” technique. During the planning phase, a surgeon could simulate the desired external femoral component rotation so that the arthroplasty trochlea was superimposed on the trochlear bone morphing at 30°, 60° and 90° knee flexion (Figs. 1 and 2). The bottom of the arthroplasty trochlea was visually aligned onto the native trochlear groove axis. The flexion gap was evaluated once the rotation had been set by using the navigation system to measure the lateral and medial tibiofemoral gap in varus and forced valgus with the knee at 90°.

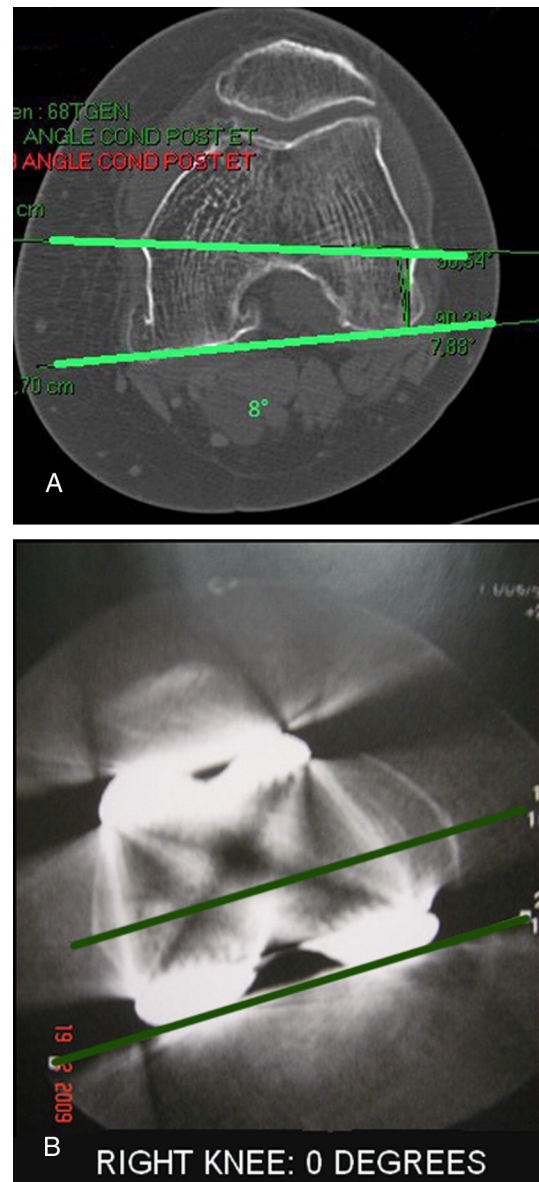
The main study outcome was the successful alignment of the femoral component parallel to the transepicondylar axis (posterior condylar angle for implant = 0°) using the navigation system. To accomplish this, it was decided in advance to perform a preoper-



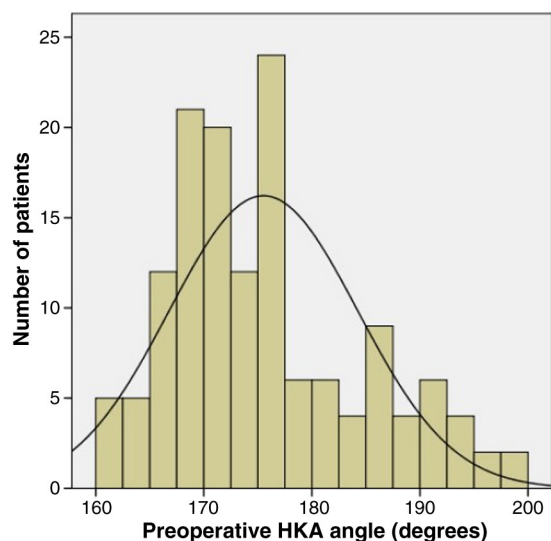
**Fig. 2.** Surgical planning view of the knee in 60° flexion after the rotation has been adjusted. The amount of rotation needed for the arthroplasty trochlea to be perfectly superimposed over the native trochlea was determined. In this case, 7° of external rotation was needed.

ative CT scan at one center and a postoperative CT scan at the other, to reduce patient irradiation and be consistent with current practices in France.

- At Center A, a preoperative CT scan of the knee was carried out (measurement of the native posterior condylar angle). The surgeon was blinded to this information during the surgical navigation. The navigation system was used to determine the rotation angle required for the femoral component. This angle was then compared to the one derived from the CT scan (Fig. 3A).
- At Center B, the surgeon navigated the knee arthroplasty and determined the femoral component rotation using only the navigation system. A postoperative CT scan was subsequently performed to verify that the posterior condylar axis of the femoral implant was parallel to the transepicondylar axis of the knee (posterior condylar angle for implant = 0°) (Fig. 3B).



**Fig. 3.** (A) Preoperative CT scan of a knee (Center A) before arthroplasty to calculate the angle between the posterior condylar axis and the transepicondylar axis. The angle was 8° in this patient. (B) Postoperative CT scan of a knee (Center B) after arthroplasty to determine the angle between the posterior condylar axis of the implant and the transepicondylar axis. The goal to obtain an alpha angle of zero (0°) was achieved since the femoral implant is parallel to the transepicondylar axis.



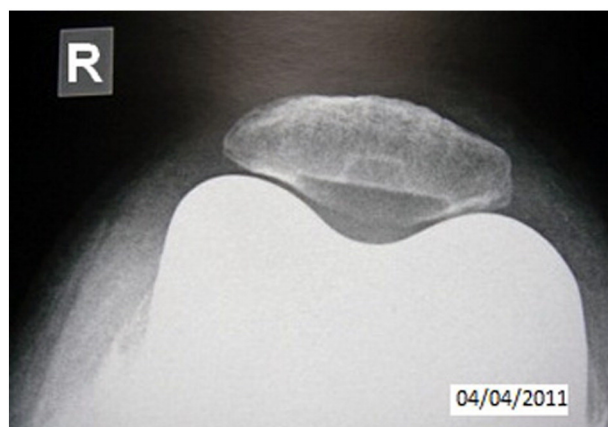**Fig. 4.** Distribution of the mechanical axis of the lower extremity (HKA angle) before surgery.

This was effectively a dual-control study where Center A tested the ability of the navigation system to give the same measured angle as the preoperative CT scan, while Center B tested the overall ability of trochlear navigation to implant the femoral component parallel to the transepicondylar axis. Before the study, the number of subjects who needed to be enrolled in a study with a 5% alpha risk and 90% power was calculated. The variance in alpha angle was estimated to be 3° on a control series of preoperative CT scans. Based on this information, a difference greater than 2° between the navigation data and CT scan data was considered significant. A minimum of 96 patients were needed for this study.

All digital data were stored on the navigation workstations and then compiled with the radiology data into a spreadsheet (Microsoft Excel). Statistical testing was performed with the SPSS software (IBM SPSS Analysis, IBM, Armonk, NY, USA). All patients were seen again at 3 months and at 1 year after the procedure. During these visits, sunrise x-ray views of the patellofemoral joint in 30° and 60° flexion were performed to measure the centering and tilting of the patella relative to the arthroplasty condyles.

## Results

No patients were lost to follow-up in this 145 patient series. Sixty-six patients were treated in Center A, and 79 in Center B. The average



**Fig. 5.** Patellofemoral sunrise view at 30° 1 year after the procedure showing that the patella is well centered over the implant.

**Table 1**

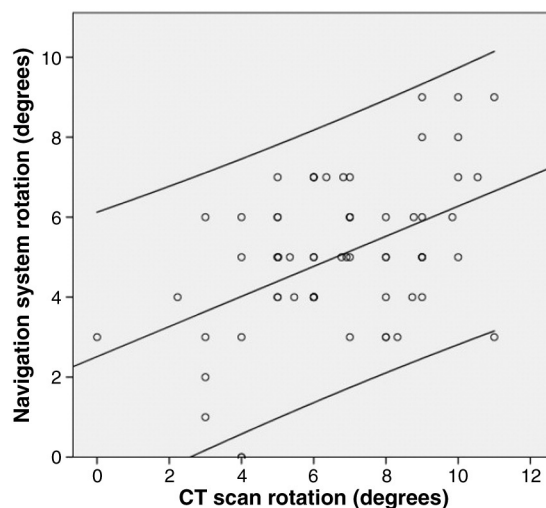
Average Values and Distribution of the Angle (Alpha Angle) between the Posterior Condylar Axis and Transepicondylar Axis.

	Minimum	Maximum	Average	Std. Dev.
CT scan rotation	0	11°	6.5°	2.32
Navigation system rotation	0	9°	5.0°	1.89

patient age was 71 years (range 53–88). Females made up 60% of the cohort. The right knee was operated on in 54% of cases. There were no significant differences in the demographic data between patients at the two centers. The average preoperative HKA angle was 175° (range 160°–200°) (Fig. 4). The varus–valgus distribution was unremarkable. The patellofemoral anatomy results were evaluated on sunrise views with the knee in 30° and 60° flexion. Only 2 of the 145 patients had a patella that was significantly off-center (more than 3 mm) relative to the bottom of the trochlea. These two patients presented with preoperative lateral patellar subluxation. Only three patients had a patellar tilt greater than 10°. The other knees (93%) had a perfectly centered patella at the 3-month and 1-year follow-ups, with no significant tilting (Fig. 5).

To evaluate the precision and reproducibility of this method, the results obtained through navigation were directly compared to those obtained with CT scanning (either preoperative or postoperative). These rotational data are described in Table 1. The two average values differed by 1.5°. There were no negative alpha angles measured by either the navigation method or CT scan. Although it was interesting to compare the average values, a supplementary analysis was required to make sure the two methods were truly consistent for a given rotation value. The relationship between the values derived from both methods is shown in Fig. 6. The difference observed at the two centers, 4.3° and 5° respectively, was not statistically significant (ANOVA) (Fig. 7). To evaluate the hypothesis that the median of the differences between the CT scan rotation and navigation system rotation was equal to 0, a Wilcoxon non-parametric test was used. The finding was significant ( $P < 0.001$ ), which indicates good agreement between the rotation values provided by these two methods.

The other crucial aspect of this study was ensuring that setting the femoral component rotation by trochlear navigation was not detrimental to the flexion gap. A balanced flexion gap was achieved after the femoral component rotation had been set (Fig. 8). In this series, balancing at 90° flexion is sufficient since the difference



**Fig. 6.** Relationship between the angular deviations in the posterior condylar axis as provided by the navigation system and the CT scan analysis. The Pearson correlation coefficient was 0.46.

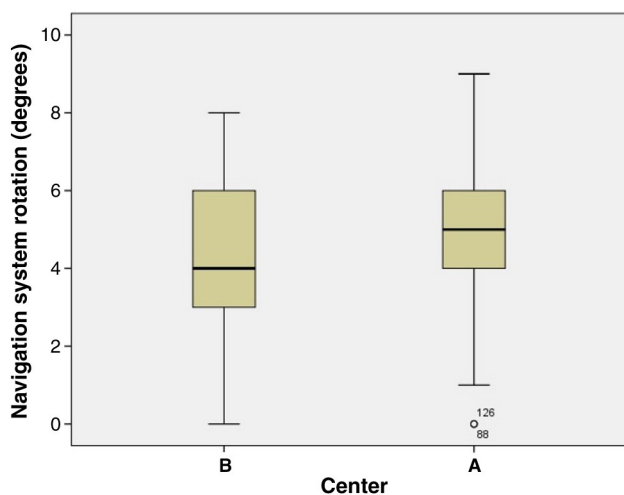


Fig. 7. Comparison between the distribution of angular deviations in the posterior condylar axis at Centers A and B.

between the medial and lateral tibiofemoral gap was never greater than 2 mm. In 78% of cases, this difference was less than 1 mm.

## Discussion

Patellofemoral complications are a common cause of revision for total knee arthroplasty [12–15]. The rotational alignment of the femoral component directly affects the patellofemoral joint and as a consequence, the clinical results [3,14–17]. The femoral component rotation must be set with the same precision as when the component is aligned in the frontal and sagittal planes [16,18,19]. It seems natural to want to properly center the patella in the arthroplasty trochlea. The current method makes this a basic tenet, since this centering process determines the rotation given to the femoral component.

The anatomical results seen on patellofemoral 30° and 60° sunrise views seem highly satisfactory in comparison to those typically reported in published studies [12]. Although this study was not designed to show that trochlear navigation improves clinical results for total knee arthroplasty, it is likely that the number of complications related to patella subluxation or dislocation could be reduced.

The results (Table 1) confirm the large variability between individuals in the alpha angle (angle formed by the posterior condylar axis and the transepicondylar axis), with values ranging from 0° to 11° [8,20–25]. This variability condemns any method that sets the external rotation a priori to a fixed, predetermined value (often 3° for those who follow this line of thought).

In the current study, the alpha angle measured with the navigation system was very close to the one measured with the CT scan (5° versus 6.5°). For a given rotational value, the measurements obtained with the two methods were consistent and positively correlated to each other (Fig. 6). Similar results were obtained in the two different centers using this technique (Fig. 7). Overall, these results show that trochlear navigation is a reliable and reproducible method for setting femoral component rotation.

Many published studies have shown that it is difficult to locate the transepicondylar axis, either visually or by navigation [4,6,26]. None of the published methods allow the femoral component rotation to be adjusted in a precise and reproducible manner [3]. The novel technique presented here seems to achieve the high precision and reproducibility needed to achieve this objective.

One potential criticism of this technique is that aligning the arthroplasty trochlea under the extensor mechanism could lead to problems with flexion symmetry. The data presented in Fig. 8 invalidate this criticism. A rectangular flexion gap was maintained when the rotation was set with trochlear navigation. This method is

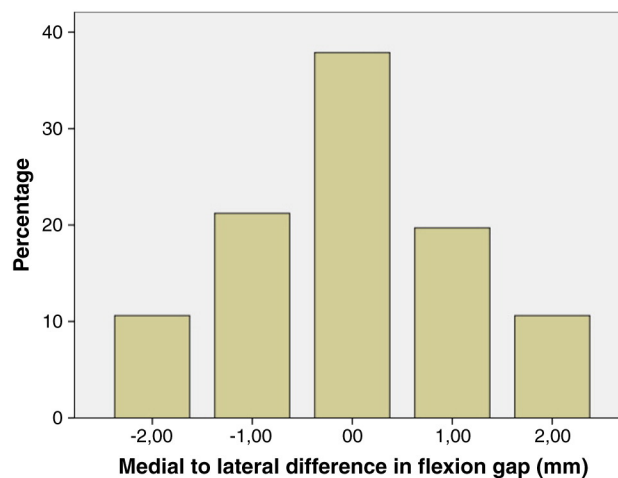


Fig. 8. Difference between the lateral and medial sides in the flexion gap (mm) as measured by the navigation system with the knee at 90°.

even more valuable when the patient initially presents with significant angular deformity. Extensive ligament release in extension can uncontrollably change the flexion gap. In these cases, the tensor method may result in abnormal femoral component rotation. The technique described here does not have this problem. All major rotational defects in the alignment of the femoral component were eliminated when using trochlear navigation. In the current study, none of the femoral components were positioned in internal rotation, as verified by postoperative CT scan.

The method used here to determine the femoral component rotation when performing total knee arthroplasty could also be applied to the alignment of the trochlear implant during isolated patellofemoral arthroplasty.

## Conclusion

This study showed that trochlear navigation is an original, reliable and reproducible method for setting the femoral component rotation during knee arthroplasty. This method was more precise than other published methods. By avoiding rotational misalignment, potential negative anatomical and clinical consequences are also avoided. This technique will have to be repeated by other surgeons to confirm our results.

## References

- Dorr LD, Boiardo RA. Technical considerations in total knee arthroplasty. *Clin Orthop Relat Res* 1986;205:5 [Research Support, Non-U.S. Gov't].
- Rhoads DD, Noble PC, Reuben JD, et al. The effect of femoral component position on patellar tracking after total knee arthroplasty. *Clin Orthop Relat Res* 1990;260:43.
- Briard JL, Hungerford DS. Patellofemoral instability in total knee arthroplasty. *J Arthroplasty* 1989;4(Suppl):S87.
- Yau WP, Chiu KY, Tang WM. How precise is the determination of rotational alignment of the femoral prosthesis in total knee arthroplasty: an in vivo study. *J Arthroplasty* 2007;22(7):1042 [Comparative Study].
- Michaut M, Beaufils P, Galaud B, et al. Rotational alignment of femoral component with computed-assisted surgery (CAS) during total knee arthroplasty. *Rev Chir Orthop Reparatrice Appar Mot* 2008;94(6):580.
- Jenny JY, Boeri C. Low reproducibility of the intra-operative measurement of the transepicondylar axis during total knee replacement. *Acta Orthop Scand* 2004;75(1):74 [Evaluation Studies].
- Jerosch J, Peuker E, Philipps B, et al. Interindividual reproducibility in perioperative rotational alignment of femoral components in knee prosthetic surgery using the transepicondylar axis. *Knee Surg Sports Traumatol Arthrosc* 2002;10(3):194.
- Mantas JP, Bloebaum RD, Skedros JG, et al. Implications of reference axes used for rotational alignment of the femoral component in primary and revision knee arthroplasty. *J Arthroplasty* 1992;7(4):531 [Research Support, U.S. Gov't, Non-P.H.S.].
- Griffin FM, Insall JN, Scuderi GR. The posterior condylar angle in osteoarthritic knees. *J Arthroplasty* 1998;13(7):812 [Comparative Study].

10. Katz MA, Beck TD, Silber JS, et al. Determining femoral rotational alignment in total knee arthroplasty: reliability of techniques. *J Arthroplasty* 2001;16(3):301 [Comparative Study].
11. Whiteside LA, Arima J. The anteroposterior axis for femoral rotational alignment in valgus total knee arthroplasty. *Clin Orthop Relat Res* 1995;321:168.
12. Berger RA, Crossett LS, Jacobs JJ, et al. Malrotation causing patellofemoral complications after total knee arthroplasty. *Clin Orthop Relat Res* 1998;356:144 [Case Reports].
13. Matsuda S, Miura H, Nagamine R, et al. Effect of femoral and tibial component position on patellar tracking following total knee arthroplasty: 10-year follow-up of Miller–Galante I knees. *Am J Knee Surg* 2001;14(3):152 [Comparative Study].
14. Akagi M, Matsusue Y, Mata T, et al. Effect of rotational alignment on patellar tracking in total knee arthroplasty. *Clin Orthop Relat Res* 1999;366:155 [Comparative Study].
15. Anouchi YS, Whiteside LA, Kaiser AD, et al. The effects of axial rotational alignment of the femoral component on knee stability and patellar tracking in total knee arthroplasty demonstrated on autopsy specimens. *Clin Orthop Relat Res* 1993;287:170.
16. Nagamine R, Miura H, Inoue Y, et al. Reliability of the anteroposterior axis and the posterior condylar axis for determining rotational alignment of the femoral component in total knee arthroplasty. *J Orthop Sci* 1998;3(4):194.
17. Boldt JG, Stiehl JB, Munzinger U, et al. Femoral component rotation in mobile-bearing total knee arthroplasty. *Knee* 2006;13(4):284.
18. Anglin C, Ho KC, Briard JL, et al. In vivo patellar kinematics during total knee arthroplasty. *Comput Aided Surg* 2008;13(6):377.
19. Berger RA, Rubash HE, Seel MJ, et al. Determining the rotational alignment of the femoral component in total knee arthroplasty using the epicondylar axis. *Clin Orthop Relat Res* 1993;286:40.
20. Cheng T, Zhang G, Zhang X. Imageless navigation system does not improve component rotational alignment in total knee arthroplasty. *J Surg Res* 2010.
21. Classen T, Wegner A, Muller RD, et al. Femoral component rotation and Laurin angle after total knee arthroplasty. *Acta Orthop Belg* 2010;76(1):69.
22. Abadie P, Galaud B, Michaut M, et al. Distal femur rotational alignment and patellar subluxation: a CT scan in vivo assessment. *Orthop Traumatol Surg Res* 2009;95(4):267.
23. Saragaglia D, Picard F, Chaussard C, et al. Computer-assisted knee arthroplasty: comparison with a conventional procedure. Results of 50 cases in a prospective randomized study. *Rev Chir Orthop Reparatrice Appar Mot* 2001;87(1):18.
24. Victor J. Rotational alignment of the distal femur: a literature review. *Orthop Traumatol Surg Res* 2009;95(5):365 [Review].
25. Boisrenoult P, Scemama P, Fallet L, et al. Epiphyseal distal torsion of the femur in osteoarthritic knees. A computed tomography study of 75 knees with medial arthrosis. *Rev Chir Orthop Reparatrice Appar Mot* 2001;87(5):469.
26. Han HS, Seong SC, Lee S, et al. Rotational alignment of femoral components in total knee arthroplasty: nonimage-based navigation system versus conventional technique. *Orthopedics* 2006;29(10 Suppl):S148 [Randomized Controlled Trial].